



**GOVERNMENT OF KARNATAKA**

No: HFW 403 ACS 2020

Karnataka Government Secretariat  
Vikasa Soudha,  
Bengaluru, Dated: 15.10.2020

**CIRCULAR**

Subject: Syndromic approach to covid-19 disease

\*\*\*

Viral infections **manifest as varied clinical syndrome**, which are similar to many other pathogens. Hence, it is not possible to confirm the diagnosis of patients with COVID-19 or Influenza infection without a diagnostic test.

And many times, in spite of clinical-radiological features suggestive of COVID-19 disease, the **RT-PCR test, which is considered as Gold Standard Test**, may be negative. With sensitivity and specificity of RT-PCR tests for nasal & throat swab ranging between 60-70%, we may miss many positive cases, i.e **false negative reports. Standard Q COVID-19 Ag rapid antigen detection test**, which is recommended by the ICMR has shown sensitivity (i.e. ability to detect true positives) ranging from 50.6% to 84% and specificity (i.e. ability to detect true negatives) of 99.3 to 100%, after two independent evaluations. Additionally, several retrospective studies have shown that **CT Thorax has greater sensitivity (86%-98%) and lower false-negative rate than RT-PCR.**

With increase in the spread of COVID-19 disease in the country and state along with increase in the number of tests every day, **the percentage of False Negative Reports are increasing** and it's expected to increase further in future.

Hence, a proxy syndrome, called **COVID-19 Like Syndrome (or) COVID-19 Probable case**, has to be used to identify such cases with correlation of clinical features, CT Thorax findings & laboratory investigations, so that we can initiate treatment similar in lines to COVID-19 confirmed cases as early as possible, to reduce the spread of infection, morbidity & mortality.

## WHO COVID-19 related definitions

Contact	<p>A contact is defined as anyone with the following exposures to a COVID-19 case, from 2 days before to 14 days after the case's onset of illness:</p> <ul style="list-style-type: none"> <li>• Being within 1 metre of a COVID-19 case for &gt;15 minutes;</li> <li>• Direct physical contact with a COVID-19 case;</li> <li>• Providing direct care for patients with COVID-19 disease without using proper personal protective equipment (PPE);</li> <li>• Other definitions, as indicated by local risk assessments.</li> </ul> <p>If confirmed cases are asymptomatic, contacts should be managed in the same way as for a symptomatic case with an exposure period from 2 days before the case was sampled, to 14 days after</p>
Suspected COVID-19 case	<p>Suspected COVID-19 case (two suspected case definitions A or B):</p> <p>A. A person who meets the clinical and epidemiological criteria:</p> <p><u>Clinical criteria:</u></p> <ol style="list-style-type: none"> <li>1. Acute onset of fever and cough;</li> <li>or</li> <li>2. Acute onset of any three or more of the following signs or symptoms: fever, cough, general weakness/fatigue, headache, myalgia, sore throat, coryza, dyspnoea, anorexia/nausea/vomiting, diarrhoea, altered mental status.</li> </ol> <p><b>AND</b></p> <p><u>Epidemiological criteria:</u></p> <ol style="list-style-type: none"> <li>1. Residing or working in an area with high risk of transmission of the virus: for example, closed residential settings and humanitarian settings, such as camp and camp-like settings for displaced persons, any time within the 14 days prior to symptom onset;</li> <li>or</li> <li>2. Residing in or travel to an area with community transmission anytime within the 14 days prior to symptom onset;</li> <li>or</li> <li>3. Working in health setting, including within health facilities and within households, anytime within the 14 days prior to symptom onset.</li> </ol> <p>B. A patient with severe acute respiratory illness (SARI: acute respiratory infection with history of fever or measured fever of <math>\geq 38\text{ }^{\circ}\text{C}</math>; and cough; with onset within the last 10 days; and who requires hospitalization).</p>
Probable COVID-19 case	<p>A. A patient who meets clinical criteria above and is a contact of a probable or confirmed case, or epidemiologically linked to a cluster of cases which has had at least one confirmed case identified within that cluster.</p> <p>B. A suspected case (described above) with chest imaging showing findings suggestive of COVID-19 disease*</p> <p>* Typical chest imaging findings suggestive of COVID-19 include the following (Manna 2020):</p> <ul style="list-style-type: none"> <li>• chest radiography: hazy opacities, often rounded in morphology, with peripheral and lower lung distribution</li> <li>• chest CT: multiple bilateral ground glass opacities, often rounded in morphology, with peripheral and lower lung distribution</li> <li>• lung ultrasound: thickened pleural lines, B lines (multifocal, discrete, or confluent), consolidative patterns with or without air bronchograms.</li> </ul> <p>C. A person with recent onset of anosmia (loss of smell) or ageusia (loss of taste) in the absence of any other identified cause.</p> <p>D. Death, not otherwise explained, in an adult with respiratory distress preceding death AND who was a contact of a probable or confirmed case or epidemiologically linked to a cluster which has had at least one confirmed case identified within that cluster.</p>
Confirmed COVID-19 Case	<p>A person with laboratory confirmation of COVID-19 infection, irrespective of clinical signs and symptoms.</p>



## **A. CLINICAL FEATURES OF COVID-19 DISEASE**

### 1. Any ILI and SARI cases

- ILI is defined as one with acute respiratory infection
  - with fever  $\geq 38^{\circ}\text{C}$  ( $100.4^{\circ}\text{F}$ ) and
  - cough
  - with onset within last 10 days
- SARI is defined as one with acute respiratory infection
  - with fever  $\geq 38^{\circ}\text{C}$  ( $100.4^{\circ}\text{F}$ ),
  - cough
  - with onset within the last 10 days and
  - requiring hospitalization

### 2. Symptoms in detail to look for:

Common Symptoms Observed	
<ul style="list-style-type: none"> <li>• Fever (87.9%),</li> <li>• Dry cough (67.7%),</li> <li>• Fatigue (38.1%),</li> <li>• Sputum production (33.4%),</li> <li>• Shortness of breath (18.6%),</li> <li>• Sore throat (13.9%),</li> <li>• Headache (13.6%),</li> <li>• Myalgia or arthralgia (14.8%),</li> </ul>	<ul style="list-style-type: none"> <li>• Chills (11.4%),</li> <li>• Nausea or vomiting (5.0%),</li> <li>• Nasal congestion (4.8%),</li> <li>• Diarrhea (3.7%), and</li> <li>• Hemoptysis (0.9%), and</li> <li>• Conjunctival congestion (0.8%)</li> <li>• Smell and taste disorders (eg:anosmia/dysgeusia)</li> </ul>

### 3. Extra Pulmonary manifestations to look for:

<b>Neurologic</b>	<b>Headache, Dizziness, Encephalopathy, GB Syndrome, Ageusia, Myalgia, Anosmia &amp; Stroke</b>
<b>Cardiac</b>	Myocarditis, Myocardial injury & Ischemia, Cardiomyopathy, Arrhythmias, Cardiogenic Shock, acute cor pulmonale
<b>Thromboembolism</b>	Deep vein thrombosis, Pulmonary embolism, Catheter – related thrombosis
<b>Renal</b>	Acute kidney injury, proteinuria, Hematuria
<b>Hepatic</b>	Elevated Aminotransferases, Elevated Bilirubin
<b>Gastrointestinal</b>	Diarrhea, nausea/vomiting, abdominal pain, anorexia
<b>Endocrine</b>	Hyperglycemia, diabetic Ketoacidosis
<b>Dermatological</b>	Petechiae, livedo reticularis, erythematous rash, urticaria, vesicles, pernio-like lesions



## **B. RADIOLOGICAL EVIDENCE OF COVID-19 DISEASE:**

**CORAD score: is a CT-based system that is used to assess the suspicion of pulmonary involvement in COVID-19.**

**For details please refer to ANNEXURE -1**

*Mathias Prokop et al. CO-RADS: A Categorical CT Assessment Scheme for Patients Suspected of Having COVID-19—Definition and Evaluation. Radiology: Volume 296: Number 2—August 2020. Radiology 2020; 296:E97–E104; <https://doi.org/10.1148/radiol.2020201473>. radiology.rsna.org*

### **Overview of CO-RADS Categories And The Corresponding Level Of Suspicion For Pulmonary Involvement In COVID-19**

CO-RADS Category	Level of Suspicion for Pulmonary Involvement of COVID-19	Summary
0	Not interpretable	Scan technically insufficient for assigning a score
1	Very low	Normal or noninfectious
2	Low	Typical for other infection but not COVID-19
3	Equivocal/unsure	Features compatible with COVID-19 but also other diseases
4	High	Suspicious for COVID-19
5	Very high	Typical for COVID-19
6	Proven	RT-PCR positive for SARS-CoV-2

Note.—CO-RADS = COVID-19 Reporting and Data System, COVID-19 = coronavirus disease 2019, RT-PCR = reverse transcription-polymerase chain reaction, SARS-CoV-2 = severe acute respiratory syndrome coronavirus 2.

### **Typical Features for Pulmonary Involvement of COVID-19**

Obligatory Features
Ground-glass opacities, with or without consolidations, in lung regions close to visceral pleural surfaces, including the fissures (subpleural sparing is allowed) and multifocal bilateral distribution
Confirmatory Patterns
Ground-glass regions
Unsharp demarcation, (half) rounded shape
Sharp demarcation, outlining the shape of multiple adjacent secondary pulmonary lobules
Crazy paving
Patterns compatible with organizing pneumonia
Thickened vessels within parenchymal abnormalities found in all confirmatory patterns



## **RSNA Consensus statement (For details please refer to **refer to Annexure -2**)**

Scott Simpson DO et al . Radiological Society of North America Expert Consensus Statement on Reporting Chest CT Findings Related to COVID-19. Endorsed by the Society of Thoracic Radiology, the American College of Radiology, and RSNA.

COVID-19 pneumonia imaging classification	Rationale	CT Findings <sup>+</sup>	Suggested Reporting Language
<b>Typical Appearance</b>	Commonly reported imaging features of greater specificity for COVID-19 pneumonia.	Peripheral, bilateral , GGO* with or without consolidation or visible intralobular lines ("crazy-paving")  Multifocal GGO of rounded morphology with or without consolidation or visible intralobular lines ("crazy-paving")  Reverse halo sign or other findings of organizing pneumonia (seen later in the disease)	"Commonly reported imaging features of (COVID-19) pneumonia are present.  Other processes such as influenza pneumonia and organizing pneumonia, as can be seen with drug toxicity and connective tissue disease, can cause a similar imaging pattern." [Cov19Typ]^
<b>Indeterminate appearance</b>	Nonspecific imaging features of COVID-19 pneumonia.	<b>Absence of typical features AND</b>  <b>Presence of:</b> Multifocal, diffuse, perihilar, or unilateral GGO with or without consolidation lacking a specific distribution and are non-rounded or non-peripheral.  Few very small GGO with a non-rounded and non-peripheral distribution	"Imaging features can be seen with (COVID-19) pneumonia, though are nonspecific and can occur with a variety of infectious and noninfectious processes." [Cov19Ind]^
<b>Atypical appearance</b>	Uncommonly or not reported features of COVID-19 pneumonia.	<b>Absence of typical or indeterminate features AND</b>  <b>Presence of:</b> Isolated lobar or segmental consolidation without GGO Discrete small nodules (centrilobular, "tree-in-bud")  Lung cavitation Smooth interlobular septal thickening with pleural effusion	"Imaging features are atypical or uncommonly reported for (COVID-19) pneumonia. Alternative diagnoses should be considered." [Cov19Aty]^
<b>Negative for pneumonia</b>	No features of pneumonia	No CT features to suggest pneumonia.	"No CT findings present to indicate pneumonia. (Note: CT may be negative in the early stages of COVID-19.) [Cov19Neg]^

## **CT SEVERITY SCORE (TOTAL SCORE 25)**

(Chang YC, Yu CJ, Chang SC, et al. Pulmonary sequelae in convalescent patients after severe acute respiratory syndrome: evaluation with thin-section CT. Radiology. 2005;236:1067–1075)

THERE ARE TWO LUNGS. Right Lung and Left Lung. Right lung is divided in three lobes. UPPER LOBE, MIDDLE LOBE, LOWER LOBE. Left lung is divided in two lobes. UPPER LOBE AND LOWER LOBE

EACH LOBE IS GIVEN SCORE 1 TO 5 BASED ON LUNG INVOLVEMENT.

**Scoring system ( SINGLE LOBE):**

5 % INFECTED: SCORE 1

5-25 % INFECTED : SCORE 2

25-50 % INFECTED : SCORE 3

50-75 % INFECTED : SCORE 4

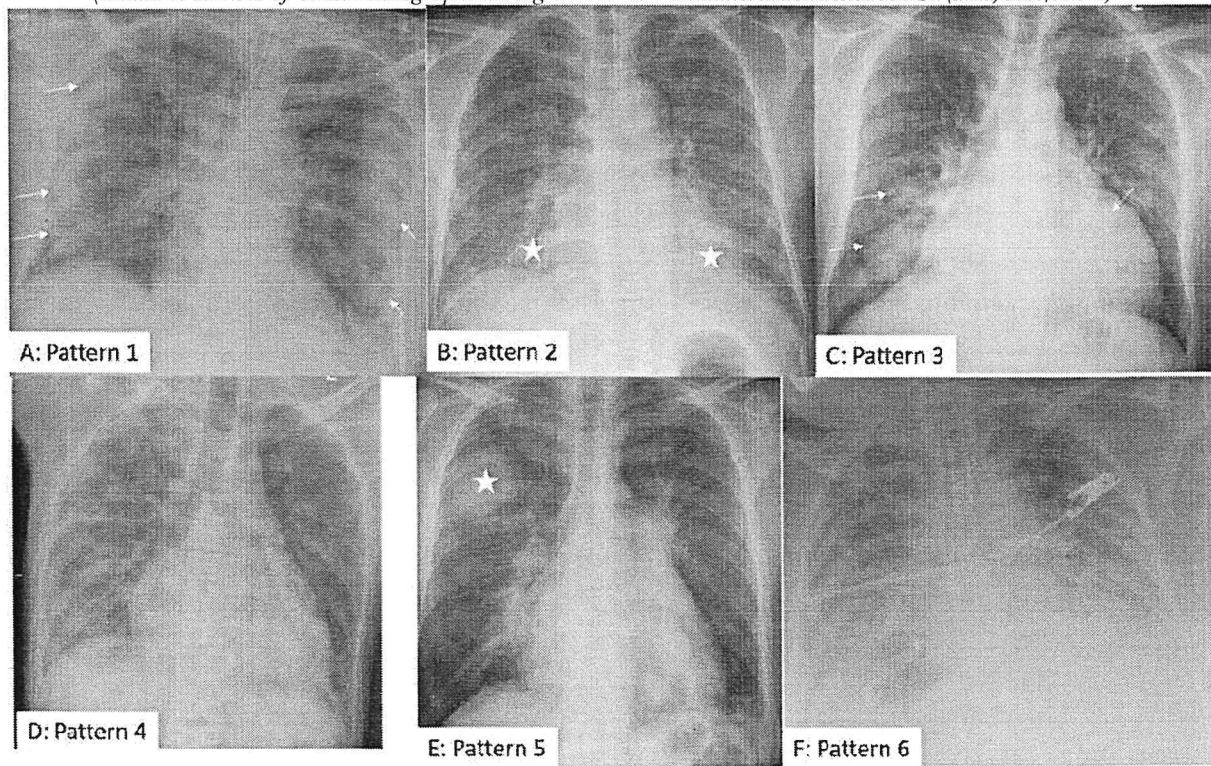
>75 % INFECTED : SCORE 5

- Score calculation is done based on each lobe involvement.
- Each lobe has maximum score 5. And so 5 lobes has maximum score of 25.
- For example, score 5 means that lobe is > 75% involved or affected by COVID-19.

SCORE	CT SEVERITY
<8	Mild
9-15	Moderate
>15	Severe

**CHEST X RAY Interpretation in COVID-19 Suspect**

(Bhalla et al. Role of Chest Radiographs during COVID-19 Pandemic. Ann Natl Acad Med Sci (India) 2020;00:1-6)



CXR patterns of COVID-19 pneumonia. (A) Pattern 1: Peripheral reverse bat-wing (arrows) (B) Pattern 2: Lower and midzones GGO/consolidation (asterisk) (C) Pattern 3: Peribronchial consolidation (arrows) (D) Pattern 4: Multifocal nonspecific distribution (E) Pattern 5: Nodular/ mass-like (asterisk) (F) Pattern 6: ARDS. **It should be known that in a given patient more than one pattern can coexist**

The reported sensitivity of CXR in diagnosis of COVID-19 ranges from 33.3 to 69%. This sensitivity is lower than that of CT scans (up to 98%), and that of initial RT-PCR. It has, however, been shown that CXR may be abnormal

*[Handwritten signature]*

in some patients, even when initial RT-PCR is negative. Hence, in view of the various advantages, it is likely to be a useful tool during the pandemic at present

### **Chest X Ray Reporting**

A critical point while reporting the CXR is that it should be viewed in optimal viewing conditions, preferably on a picture archiving and communication system (PACS) with appropriate monitor by a qualified radiologist.

*Normal:* CXR normal; COVID-19 not excluded.

*Classic/probable COVID-19:* Lower lobe predominant and peripheral predominant; multiple, bilateral, areas of GGOs

*Indeterminate:* Does not fit into classic/non-COVID pattern

*Non-COVID pattern:* Pneumothorax, lobar consolidation, pleural effusion, and pulmonary edema

### **WHO recommendations for usage of chest imaging in diagnosis of COVID-19**

Recommendations	Remarks
For asymptomatic contacts of patients with COVID-19, WHO suggests not to use chest imaging for the diagnosis of COVID-19.	RT-PCR should be done to confirm diagnosis.
For symptomatic patients with suspected COVID-19, WHO suggests not to use chest imaging for the diagnostic workup of COVID-19 when RT-PCR testing is available with timely results.	RT-PCR should be done to confirm diagnosis
For symptomatic patients with suspected COVID-19, WHO suggests using chest imaging for the diagnostic workup of COVID-19 when: (1) RT-PCR testing is not available; (2) RT-PCR testing is available, but results are delayed; and (3) initial RT-PCR testing is negative, but with high clinical of suspicion of COVID-19	Imaging should be used as one element of the diagnostic workup that otherwise includes clinical and laboratory data

**Chest Imaging should not be used alone as diagnostic modality when RT-PCR facility is available.** The absence of radiological signs of COVID-19 pneumonia cannot completely exclude a COVID-19 infection. Hence, imaging should be used as one element of the diagnostic workup that otherwise includes clinical and laboratory data.

### **C. Laboratory Investigations:**

LABORATORY VALUE
Lymphopenia (<20)
CRP>100 mg/L
Serum Ferritin >300 microg/L
LDH >450
D-Dimer > 1000ng/ml

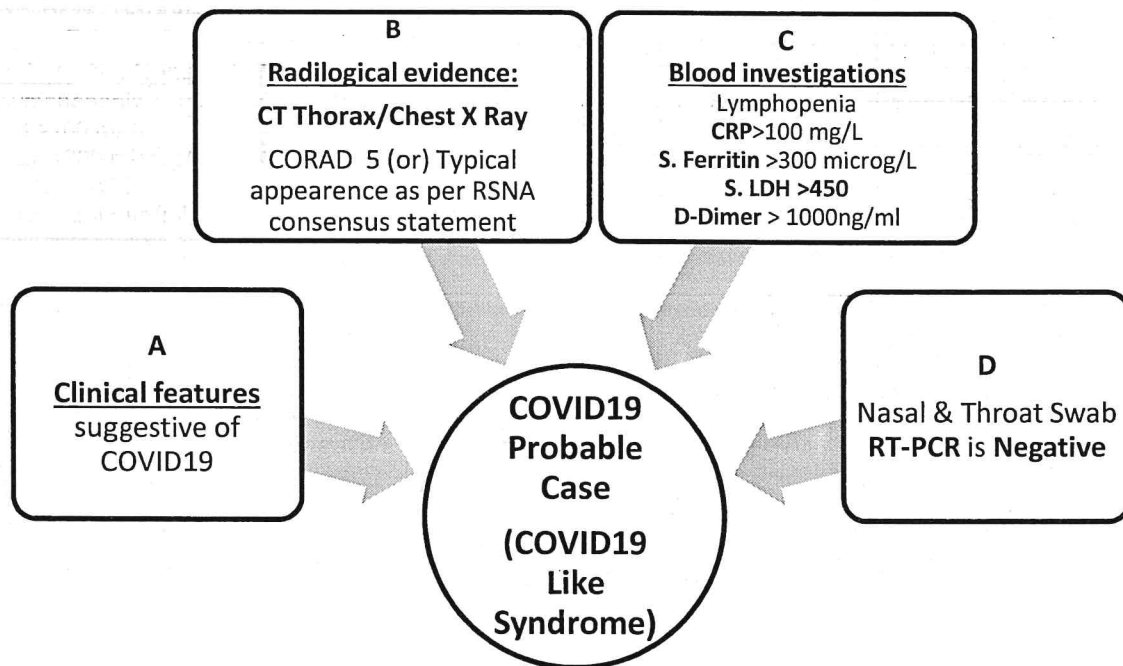
### **D. RT-PCR of Nasal & Throat Swab for COVID-19 –**

- Negative
- Delayed reporting (in critical patient)
- Not available

## **COVID-19 Like Syndrome (COVID-19 Probable Case)**

(modified from WHO definition)

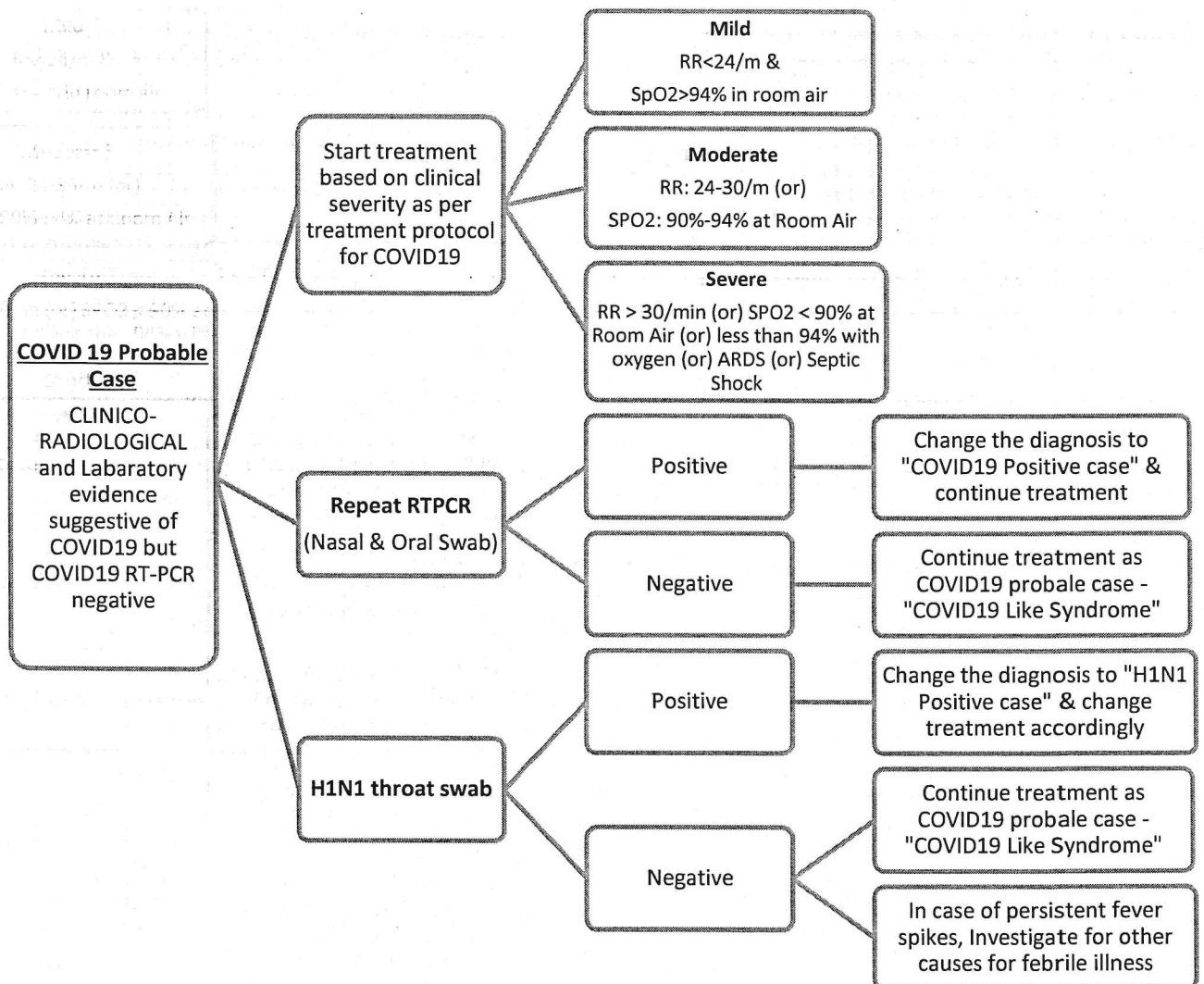
Any Suspect case who is RT-PCR Negative, but clinico- radiological evidence and laboratory values are suggestive of COVID-19 disease as per criteria mentioned below



**A+B+C+D is suggestive of Probable COVID-19 Case  
(COVID-19 Like Syndrome)**

*(Signature)*





*[Handwritten signature]*

**ALGORITHM TO MANAGE COVID-19 PROBABLE CASE (COVID-19 LIKE SYNDROME)**  
**Treatment Protocol for COVID-19 PROBABLE CASE (COVID-19 Like syndrome)**

**SUMMARY OF TREATMENT for COVID-19 PROBABLE CASE (COVID19 LIKE SYNDROME)**

**BASED on CLINICAL CATEGORIES**

MILD	MODERATE	SEVERE/CRITICAL
<p><b><u>Antiviral Therapy*</u></b></p> <p>Cap Oseltamavir 75mg 1-0-1 for 5 days</p> <p>Tab Hydroxychloroquine(HCQ) 400mg Bd For 1 Day F/B 200mg 1-0-1 X 4 Day for patients in COVID CARE CENTER/HOME ISOLATION</p> <p>(OR)</p> <p>Tab FAVIPIRAVIR 1800mg 1-0-1 on Day 1 f/b 800mg 1-0-1 for 6 days for PATIENTS IN DCHC</p> <p>(OR)</p> <p>If Tab HCQ/Tab FAVIPIRAVIR is contraindicated, then combination of</p> <p>Cap DOXYCYCLIN 100mg 1-0-1 for 5 days</p> <p>+</p> <p>Tab IVERMECTIN 12mg 1-0-0 for 3 days</p> <p><b><u>Anticoagulation</u></b></p> <p>Inj Enoxaparin 40mg S/C 1-0-0 x 7 days (If D-dimer Is More Than 1000ng/ML or X-ray/CT Thorax Showing Ground glass opacity)</p> <p><b><u>Supportive Therapy</u></b></p> <p>Tab Zinc 50 Mg 0-1-0x 7 Days</p> <p>Tab Vitamin C 500 Mg 1-1-1 X 7 Days</p> <p>Tab N Acetylcysteine 1-1-1 If Patients Having Cough</p>	<p><b><u>Antiviral Therapy*</u></b></p> <p>Cap Oseltamavir 75mg 1-0-1 for 5 days</p> <p>Tab Hydroxychloroquine(HCQ) 400mg BD For 1 Day F/B 200mg 1-0-1 X 4 Day</p> <p><b><u>STERIODS</u></b></p> <p>Inj. Methyl Prednisolone 0.5 -1 mg/kg (or) Inj. Dexamethasone 0.1 – 0.2 mg /kg for 3-5 Days</p> <p><b><u>ANTICOAGULATION</u></b></p> <p>Inj Enoxaparin 40mg S/C 1-0-0 x 7 days (if Wt &gt;65kg, 60md 1-0-1 for 7days)</p> <p>Iv Antibiotics According to Local Antibigram</p> <p>Awake Proning</p> <p>Start on oxygen –Nasal Prongs 2-5l/min or face mask 5l/min</p> <p><b><u>Supportive Therapy</u></b></p> <p>Tab Zinc 50 Mg 0-1-0x 7 Days</p> <p>Tab Vitamin C 500 Mg 1-1-1 X 7 Days</p> <p>Tab N Acetylcysteine 1-1-1 If Patients Having Cough</p>	<p><b><u>Antiviral Therapy*</u></b></p> <p>Cap Oseltamavir 75mg 1-0-1 for 5 days</p> <p><b><u>STERIODS</u></b></p> <p>Inj. Methyl Prednisolone 1-2 mg/kg for 5-7 Days (or)</p> <p>Inj. Dexamethasone 0.2 – 0.4 mg /kg for 5-7 Days</p> <p><b><u>ANTICOAGULATION</u></b></p> <p>Inj Enoxaparin 1 Mg/Kg Body Weight S/C 1-0-1 X 7days</p> <p>Inj Ceftriaxone 1 Gm Iv 1-0-1 And Can Be Escalated According To Local Antibigram Or Treating Physician</p> <p>Start on oxygen with face mask+NRM and change over to HFNC/NIV (based on PaO2/FiO2)</p> <p>IF PATIENT DETERIORATES with HFNC/NIV trial (repeat ABG after 6hrs suggests worsening of oxygenation) then EARLY INTUBATION SHOULD BE CONSIDERED AND LUNG PROTECTIVE VENTILATION TO BE FOLLOWED AS PER ARDSnet PROTOCOL</p> <p>Prone Ventilation</p> <p>SEPSIVAC 0.3ml INTRADERMAL ONCE A DAY FOR 3 DAYS</p> <p><b><u>Supportive Therapy</u></b></p> <p>Inj. Vitamin C 1.5gm Iv 6 Hourly X 5 days</p> <p>Tab Zinc 50 Mg 0-1-0x 7 Days</p> <p>Tab N Acetylcysteine 1-1-1 If Patients Having Cough</p>

1. Continuous monitoring of oxygen saturation by pulse oximeter and early diagnosis of hypoxemia is essential in all group of patients
2. Indications and contraindications of the drugs are to be considered before use
3. Transition of patients between the clinical categories is based on SpO2, RR & PaO2/FiO2 ratio
4. Treatment of all co morbid illness to continue

**\*Special Note:**

- Inj REMDESIVIR 200 mg IV on day 1 followed by 100 mg IV daily for 4 days should be used in moderate and severe/critical category patients after detailed counseling with patient/attendees and must obtain informed written consent from the patient/attendees before usage
- Co-administration of Inj REMDESIVIR with HCQ or chloroquine should be avoided

*Paul*

## **Definition of death due to COVID-19 (by WHO)**

A COVID-19 death is defined for surveillance purposes as a death resulting from a clinically compatible illness in a **probable or confirmed COVID-19 case**, unless there is a clear alternative cause of death that cannot be related to COVID-19 disease (e.g. trauma). There should be no period of complete recovery between the illness and death.

Reporting in case of death of such patients

1. Use ICD-10 Codes for COVID-19 provided by World Health Organization
  - i. Emergency ICD-10 Code Usage conditions
    1. U07.1: COVID-19, virus identified
    2. U07.2: COVID-19, virus not identified: Clinically-epidemiologically diagnosed COVID-19, Probable COVID-19, Suspected COVID-19 (Refer to Latest ICMR Guidelines)
2. To dispose the dead body in a dignified manner with similar protocol as for COVID19 positive case (Refer to Latest GoK Guidelines)

## **DISCLAIMER:**

- This Recommendation is derived from the prevailing published studies and collation of various guidelines across the world.
- These guidelines would change with the evolving evidences

## **REFERENCES:**

1. *Use of chest imaging in COVID-19: a rapid advice guide*. Geneva: World Health Organization; 2020 (WHO/2019-nCoV/Clinical/Radiology\_imaging/2020.1). Licence: CC BY-NC-SA 3.0 IGO.
2. *Public Health Surveillance for COVID-19: Interim guidance*. (7<sup>th</sup> august 2020). WHO/2019-nCoV/SurveillanceGuidance/2020.7
3. Mathias Prokop et al. *CO-RADS: A Categorical CT Assessment Scheme for Patients Suspected of Having COVID-19—Definition and Evaluation*. Radiology: Volume 296: Number 2—August 2020. Radiology 2020; 296:E97–E104; <https://doi.org/10.1148/radiol.2020201473>. radiology.rsna.org
4. Scott Simpson DO et al. Radiological Society of North America Expert Consensus Statement on Reporting Chest CT Findings Related to COVID-19. Endorsed by the Society of Thoracic Radiology, the American College of Radiology, and RSNA.
5. Chang YC, Yu CJ, Chang SC, et al. Pulmonary sequelae in convalescent patients after severe acute respiratory syndrome: evaluation with thin-section CT. Radiology. 2005;236:1067–1075
6. Bhalla et al. Role of Chest Radiographs during COVID-19 Pandemic. Ann Natl Acad Med Sci (India) 2020;00:1–6
7. Thoracic Imaging in COVID-19 infection. Guidance for the reporting radiologist. British Society of Thoracic imaging. Version 2. 16<sup>th</sup> March 2020)
8. [https://www.icmr.gov.in/pdf/covid/techdoc/Guidance\\_appropriate\\_recording\\_of\\_related\\_deaths\\_india.pdf](https://www.icmr.gov.in/pdf/covid/techdoc/Guidance_appropriate_recording_of_related_deaths_india.pdf)
9. <https://covid19.karnataka.gov.in/storage/pdf-files/Revised%20Guidelines%20on%20dead%20body%20management.pdf>



## ANNEXURE -1

### **CO-RADS: Definition and Evaluation**

*Mathias Prokop et al. CO-RADS: A Categorical CT Assessment Scheme for Patients Suspected of Having COVID-19—Definition and Evaluation. radiology.rsna.org Radiology: Volume 296: Number 2—August 2020. Radiology 2020; 296:E97–E104; <https://doi.org/10.1148/radiol.2020201473>*

CO-RADS	Level of Suspicion for Pulmonary Involvement of COVID-19	CT Findings	Summary
<b>0</b>	<b>Not interpretable</b>	<b>Incomplete or insufficient. Ex: artifacts due to cough or breathing</b>	<b>Scan technically insufficient for assigning a score</b>
<b>1</b>	<b>Very low</b>	Normal. (Or) Mild or severe emphysema, perifissural nodules, lung tumors, and fibrosis.  * “Negative for pneumonia” as per the RSNA consensus statement	<b>Normal Or Noninfectious</b>
<b>2</b>	<b>Low</b>	Findings suggestive of bronchitis, infectious bronchiolitis, bronchopneumonia, lobar pneumonia, and pulmonary abscess. Features include tree-in-bud sign, a centrilobular nodular pattern, lobar or segmental consolidation, and lung cavitation.  **“atypical appearance” as per the RSNA consensus statement	<b>Typical for other infection but not COVID-19</b>
<b>3</b>	<b>Equivocal/unsure</b>	Findings that can also be found in other viral pneumonias or noninfectious causes: Includes peri-hilar ground-glass opacity, homogenous extensive ground-glass opacity with or without sparing of some secondary pulmonary lobules, or ground-glass opacity together with smooth interlobular septal thickening with or without pleural effusion in the absence of other typical CT findings.  Also includes small ground-glass opacities that are not centrilobular (otherwise they would be CO-RADS category 2) or not located close to the visceral pleura. (otherwise they would be CO-RADS category 4).  In addition, it contains patterns of consolidation compatible with organizing pneumonia without other typical findings of COVID-19.  *partially overlaps with the “indeterminate appearance” category of the RSNA consensus statement (lower likelihood for COVID-19)	<b>Features compatible with COVID-19 but also other diseases</b>

*Gay*



<b>4</b>	<b>High</b>	<p><b>CT findings that are typical for COVID-19 but also show some overlap with other (viral) pneumonias.</b> Findings are similar to those for CO-RADS category 5; however, they are not in contact with the visceral pleura, nor are they located strictly unilaterally in a predominant peribronchovascular distribution or superimposed on severe diffuse preexisting pulmonary abnormalities</p> <p>* “indeterminate appearance” category of the RSNA consensus statement (higher likelihood of COVID-19)</p>	<b>Suspicious for COVID-19</b>
<b>5</b>	<b>Very High</b>	<p><b>Typical CT findings:</b> Mandatory features are ground-glass opacities with or without consolidations in lung regions close to visceral pleural surfaces, including the fissures, and a multifocal bilateral distribution. Subpleural sparing can be present. Requires the presence of at least one confirmatory pattern that aligns with the temporal evolution of the disease.</p> <p>The pattern that has been described <b>early in the course</b> of COVID-19 is dominated by multiple ground-glass areas, which often show (half) rounded and unsharp demarcation but can be accompanied by sharply delineated ground-glass areas that outline the shape of multiple adjacent secondary pulmonary lobules.</p> <p>The crazy paving pattern, which has been described as <b>appearing later in the course</b> of the disease, shows visible intralobular lines.</p> <p><b>As the disease progresses</b>, more consolidations occur within the areas of ground-glass opacity. Finally, opacities that resemble organizing pneumonia occur, such as reverse halo signs or ground-glass opacity with extensive subpleural consolidations and air bronchograms.</p> <p>Subpleural curvilinear bands or bands of ground glass with or without consolidation in a tethered arching pattern with small connections to the pleura are also considered typical findings. Thickened vessels within lung abnormalities are typical and are frequently found in all other confirmatory patterns.</p> <p>*“typical appearance” of the RSNA consensus statement</p>	<b>Typical for COVID-19</b>
<b>6</b>	<b>Proven</b>	<p>Indicates proven COVID-19 as per RT-PCR Test</p> <p>*no separate category under RSNA consensus statement</p>	<b>RT-PCR positive for SARS-CoV-2</b>

*Gay*

**ANNEXURE -2**  
**RSNA Consensus Statement**

**Radiological Society of North America Expert Consensus Statement on Reporting Chest CT Findings Related to COVID-19. Endorsed by the Society of Thoracic Radiology, the American College of Radiology, and RSNA**  
**By Scott Simpson DO et al.**

<b>Proposed Reporting Language for CT Findings Related to COVID-19</b>			
Routine screening CT for diagnosis or exclusion of COVID-19 is currently not recommended by most professional organizations or the US Centers for Disease Control and Prevention			
<b>COVID-19 pneumonia imaging classification</b>	<b>Rationale</b>	<b>CT Findings+</b>	<b>Suggested Reporting Language</b>
<b>Typical appearance</b>	Commonly reported imaging features of greater specificity for COVID-19 pneumonia.	Peripheral, bilateral, GGO* with or without consolidation or visible intralobular lines ("crazy-paving")  Multifocal GGO of rounded morphology with or without consolidation or visible intralobular lines ("crazy-paving")  Reverse halo sign or other findings of organizing pneumonia (seen later in the disease)	"Commonly reported imaging features of (COVID-19) pneumonia are present.  Other processes such as influenza pneumonia and organizing pneumonia, as can be seen with drug toxicity and connective tissue disease, can cause a similar imaging pattern." [Cov19Typ]^
<b>Indeterminate appearance</b>	Nonspecific imaging features of COVID-19 pneumonia.	<b>Absence of typical features AND</b>  <b>Presence of:</b> Multifocal, diffuse, perihilar, or unilateral GGO with or without consolidation lacking a specific distribution and are non-rounded or non-peripheral.  Few very small GGO with a non-rounded and non-peripheral distribution	"Imaging features can be seen with (COVID-19) pneumonia, though are nonspecific and can occur with a variety of infectious and noninfectious processes." [Cov19Ind]^
<b>Atypical appearance</b>	Uncommonly <i>or</i> not reported features of COVID-19 pneumonia.	<b>Absence of typical or indeterminate features AND</b>  <b>Presence of:</b> Isolated lobar or segmental consolidation without GGO Discrete small nodules (centrilobular, "tree-in-bud")  Lung cavitation Smooth interlobular septal thickening with pleural effusion	"Imaging features are atypical or uncommonly reported for (COVID-19) pneumonia. Alternative diagnoses should be considered." [Cov19Aty]^
<b>Negative for pneumonia</b>	No features of pneumonia	No CT features to suggest pneumonia.	"No CT findings present to indicate pneumonia. (Note: CT may be negative in the early stages of COVID-19.) [Cov19Neg]^

*Handwritten signature*


Notes:

1. Inclusion in a report of items noted in parenthesis in the Suggested Reporting Language column may depend upon clinical suspicion, local prevalence, patient status as a PUI, and local procedures regarding reporting.
2. CT is not a substitute for RT-PCR, consider testing according to local recommendations and procedures for and availability of RT-PCR

**Pros and Cons of Standardized Reporting for Chest CT findings Related to COVID-19**

Pros and Cons of Standardized Reporting for Chest CT findings Related to COVID-19	
Routine screening CT for diagnosis or exclusion of COVID-19 is currently not recommended by most professional organizations or the US Centers for Disease Control and Prevention	
Pros	Cons
<ul style="list-style-type: none"><li>• Clinicians may be unsuspecting of COVID- 19 in atypical presentations</li><li>• Initial RT-PCR may be negative, and typical features may encourage repeat confirmatory testing</li><li>• Standardized reporting language can improve report quality and clarity by ensuring consistent terminology</li><li>• Reporting data can be used for future teaching, research, clinical quality improvement, and future management pathways</li></ul>	<ul style="list-style-type: none"><li>• The true sensitivity and specificity of chest CT are unknown. Even patients with a normal chest CT or only atypical features may have COVID- 19</li><li>• Clinicians may feel that having "COVID-19" in a report boxes them in and limits their options for patient management</li><li>• Patients may be apprehensive about having terminology like "COVID-19" or "coronavirus" in their reports and medical records</li></ul>

The above Syndromic Approach to COVID 19 is approved by the Joint Expert Committees, Rajiv Gandhi University of Health Sciences (RGUHS) & The Technical Advisory Committee of Dept. of Health & Family Welfare, Govt. of Karnataka. Hence, all the Government & Private Health Establishments treating COVID 19 persons should strictly adhere to the above approach, in the larger interest of reducing mortality due to COVID 19.

  
(Jawaid Akhtar)

Additional Chief Secretary to Government  
Department of Health & Family Welfare

**To:**

1. The Commissioner, BBMP, Bengaluru

2. The Deputy Commissioners , All Districts
3. The Chief Executive Officers, Zilla Panchayath, All Districts
4. The District Health Officer & District Surgeons – All Districts
5. The Dean cum Directors, All Medical Colleges
6. The President – IMA, IAP, PHANA, for circulation to all the members & Heads of all Private Medical Establishments.

**Copy for information to:**

1. The Chief Secretary, Government of Karnataka, Bengaluru
2. The Principal Secretary to Government, Medical Education Dept., Bengaluru
3. The Commissioner, Health & Family Welfare Services, Bengaluru
4. The Mission Director, NHM, Bengaluru
5. The Director, Health & Family Welfare Services, Bengaluru
6. The Director, Medical Education Dept., Bengaluru